

CASE STUDY

USING SMART360® AND EAGLET ESP TO DESIGN A BOSTONSIGHT SCLERAL LENS FOR KERATOCONUS

BACKGROUND

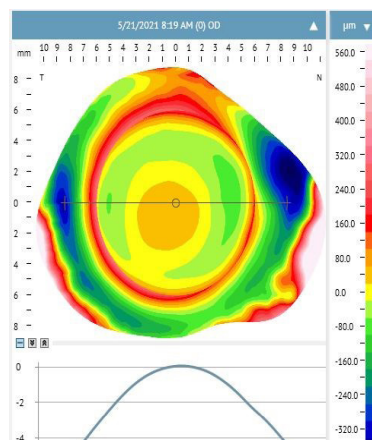
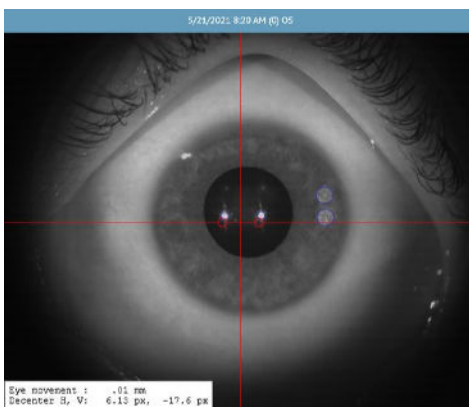
A 35-year-old male presented with bilateral keratoconus, mild in the right eye and moderate in the left eye. Left eye is also s/p corneal cross-linking from several years ago. The patient was referred for a specialty contact lens fit for OS only.

The patient was fit in 2019. At the time, using a diagnostic fitting set, I required 3 refits for a total of 4 lenses to achieve final fit. The patient had 20/25+ "unhappy vision" and was convinced he was suffering from higher-order aberrations (HOAs). There were no commercially available HOA corrective lenses available to try at this time.

PROFILOMETRY MEASUREMENT

When the patient returned in 2021, the Eye Surface Profiler (Eaglet Eye, Netherlands) and BostonSight SCLERAL's Smart360 technology were used to design a new free-form lens.

With the ESP, a scan of the ocular surface was taken gathering data from the anterior ocular surface (shown below). Once the eye scan is transferred, Smart360 uses the corneo-scleral profilometry data for a truly custom scleral lens fit.



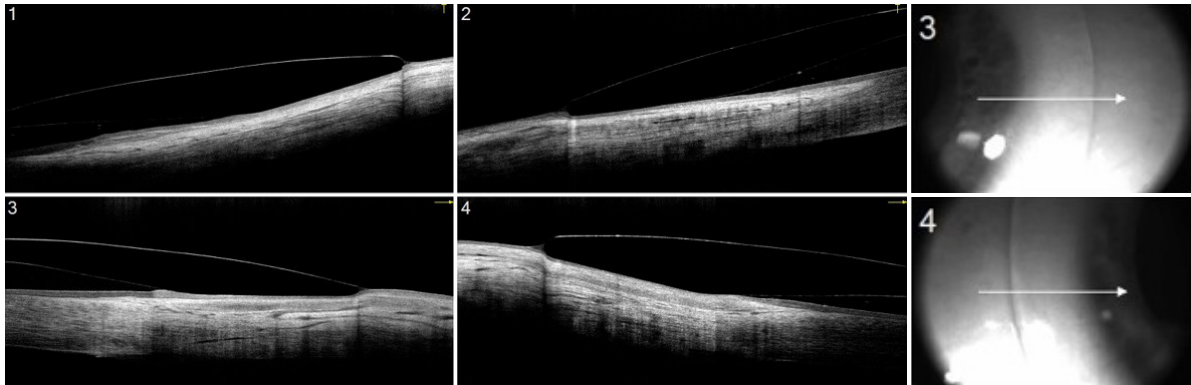
**DR. SHEILA
MORRISON**

Dr. Morrison received her Doctorate, Master's in Vision Science with focus on scleral lenses, and Residency in Cornea and Contact Lens from Pacific University College of Optometry. She served on faculty at the University of Houston College of Optometry where she facilitated education and research in the Contact Lens and Cornea service. Now she is back in Canada where she practices at Mission Eye Care Center for Dry Eye and Corneal Disease in Calgary, is a clinical rotation site instructor for the University of Waterloo College of Optometry.



SCLERAL LENS FITTING

The lens was ordered via the DirectConnect link on the ESP software, which connects to BostonSight's FitConnect® software, using the base curve the patient was wearing. No changes were required to achieve the fit from the scan. The only minor changes for the final lens were a small over-refraction of -0.50 1.00x080 and 5deg CCW rotation. First lens OCT scan (Optovue):



RESULTS

Beautiful first lens landing. The patient specifically mentioned that the fit feels excellent and was impressed with the technology.

Offering your patients profilometry based free-form scleral lenses not only impress the patients, it also cuts down on chair time and patient visits. SmartSight HOA® technology will be added soon (BostonSight).