

TIME HEALS ALL WOUNDS

Scleral Contact Lenses for Neurotrophic Keratopathy

AVANI DAVE O.D. F.A.A.O



Introduction

Neurotrophic keratopathy (NK) is an underdiagnosed corneal condition where trigeminal cranial nerve compromise leads to epithelial breakdown and poor wound healing. With widespread causes, the importance of detecting, classifying and managing NK earlier on is crucial. This case illustrates the symbiotic role of topical treatment and scleral lens management in healing, restoring and protecting the ocular surface.

Case Description

A 63-year-old female is referred to the Optometry Contact Lens clinic for recurrent epithelial defects in setting of NK (Mackie Stage 2) in her left eye. Her past surgical history includes the following: Former high myope s/p LASIK OU, retinal detachment x 2, s/p CE/IOL with IOL dislocation repair. The patient eventually develops residual persistent bullous keratopathy which leads to frequent ocular surface breakdown.

INITIAL ENCOUNTER

- OS: Count Finger vision secondary to an irregular ocular surface with multiple epithelial defects, 3+ posterior capsular opacification and epiretinal membrane
- Treatment history: Amniotic membranes x2, Valacyclovir 500 mg, punctal occlusion, lubrication with preservative free tears q4h, Moxifloxacin TID and a monthly exchange of bandage contact lens (BCL - Air Optix)

CLINICAL FINDINGS VISIT #1

- Multiple epithelial defects s/p BCL removal

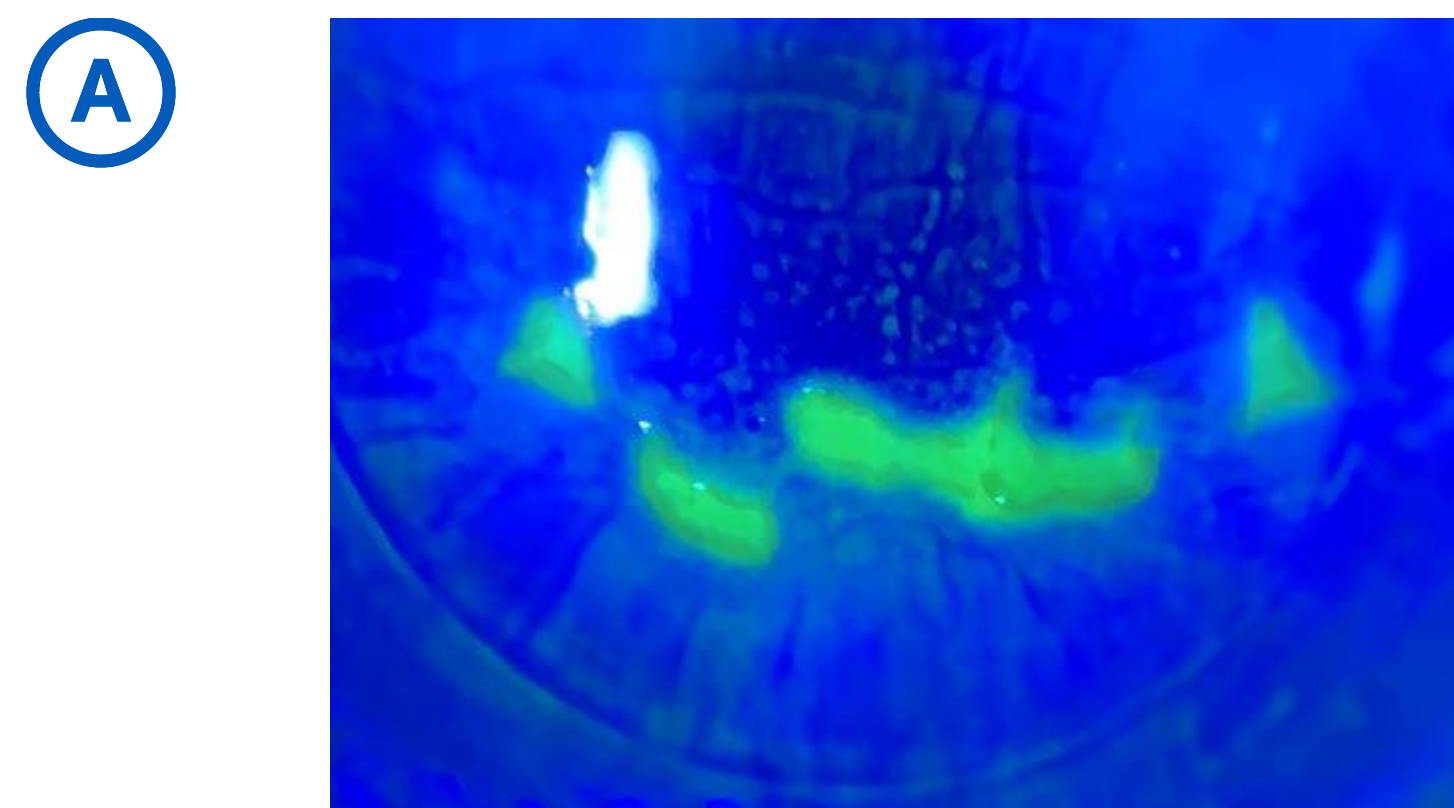


Figure A: Baseline slit lamp corneal photo, left eye

- Low Schirmer's Score of 3 mm OU
- Anesthesia OS>OD based on cotton swab corneal sensitivity testing

Topical Treatment

- Initiated on Cenergem (Oxervate) topical treatment 6x/day for eight-weeks of treatment
- Genteal ointment qhs and Preservative free tears (Refresh) every hour OS

Short-term goal: restore and regenerate the ocular surface prior to scleral contact lens fitting.

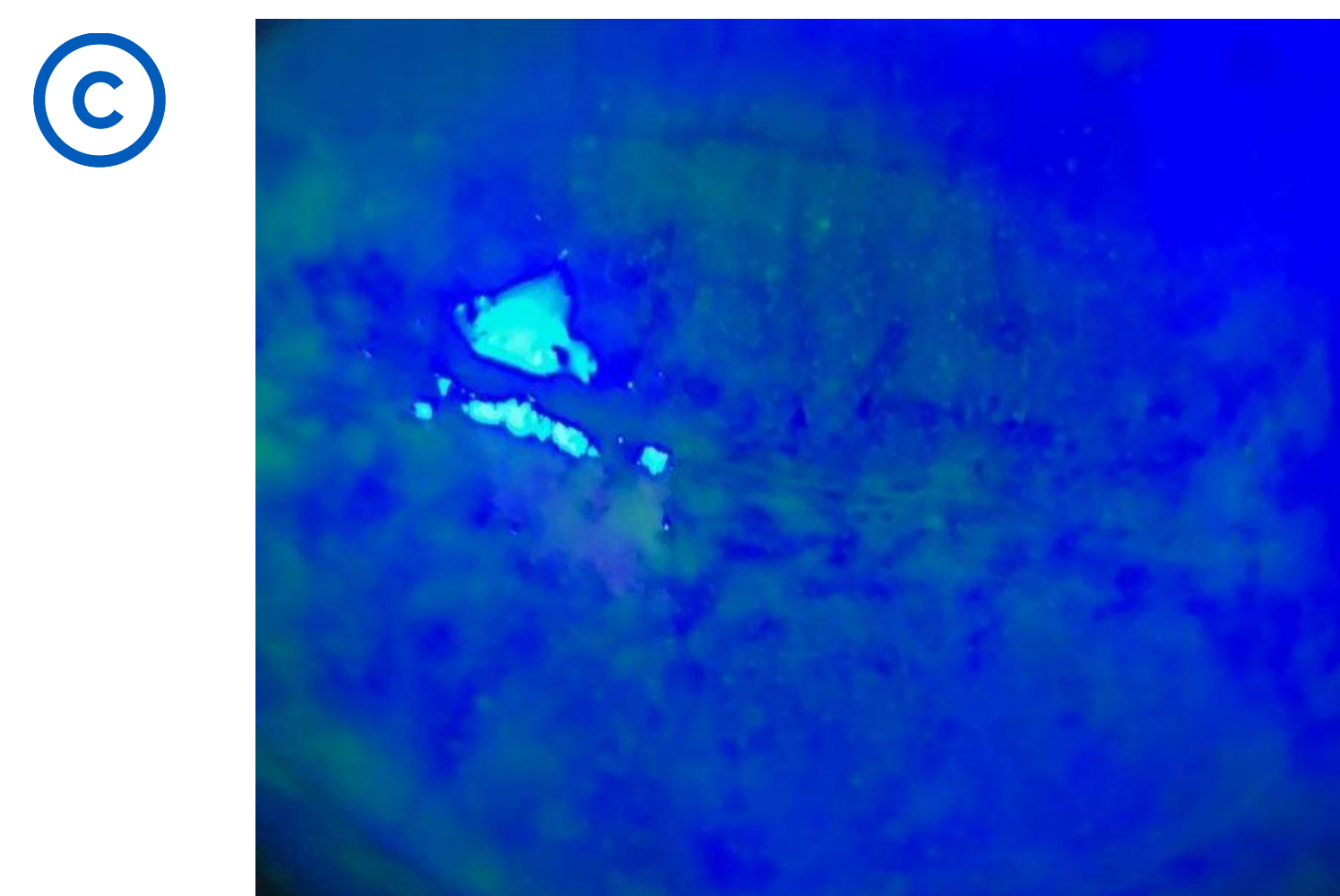
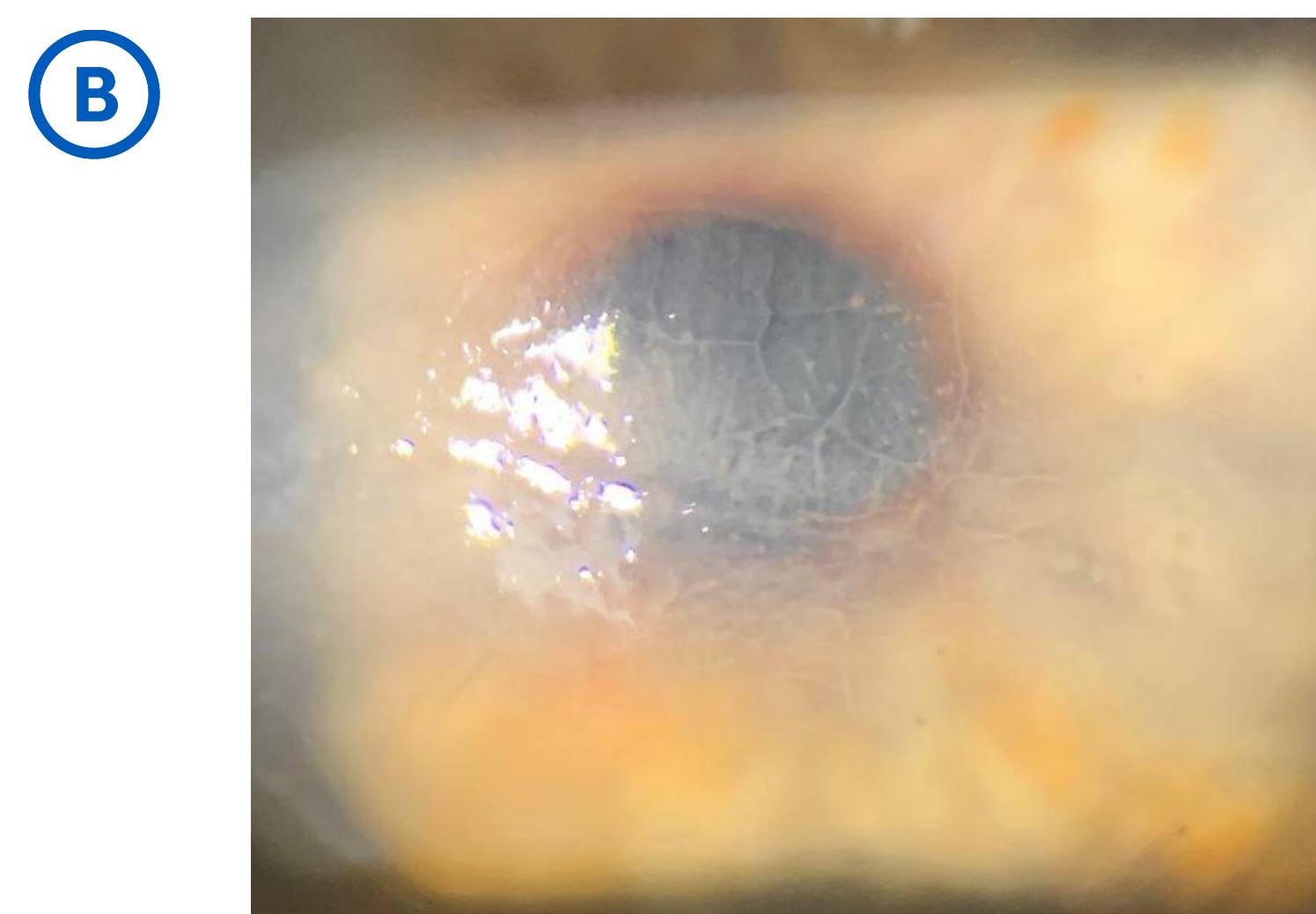


Figure B: Corneal Slit lamp photo of left eye at conclusion of Oxervate treatment, Figure C: with NaFl staining and Cobalt Blue Filter

Scleral Contact Lens Fitting

Upon conclusion of treatment, the patient has complete resolution of epithelial defects. The patient is then fit in a fenestrated scleral contact lens design for day time wear (up to 15 hours) with the fluid reservoir filled with Nutrifill saline solution and Genteal ointment post scleral removal qhs.

Long-term goal: maintain the ocular surface and preventing future breakdown.

FINAL LENS PARAMETERS

Boston Sight Scleral
18.0 mm 2770 SAG 7.9 BC
-0.28 D FSE1

Optimum Infinite, HydraPeg Haptic Fenestration, Quadrant Specific Haptics




Figure D: Optic section of scleral lens demonstrating central corneal clearance

Follow-Up Care

The ocular surface is monitored at intervals of one month, three months, six months and one year of successful full time daily wear of scleral lens OS.

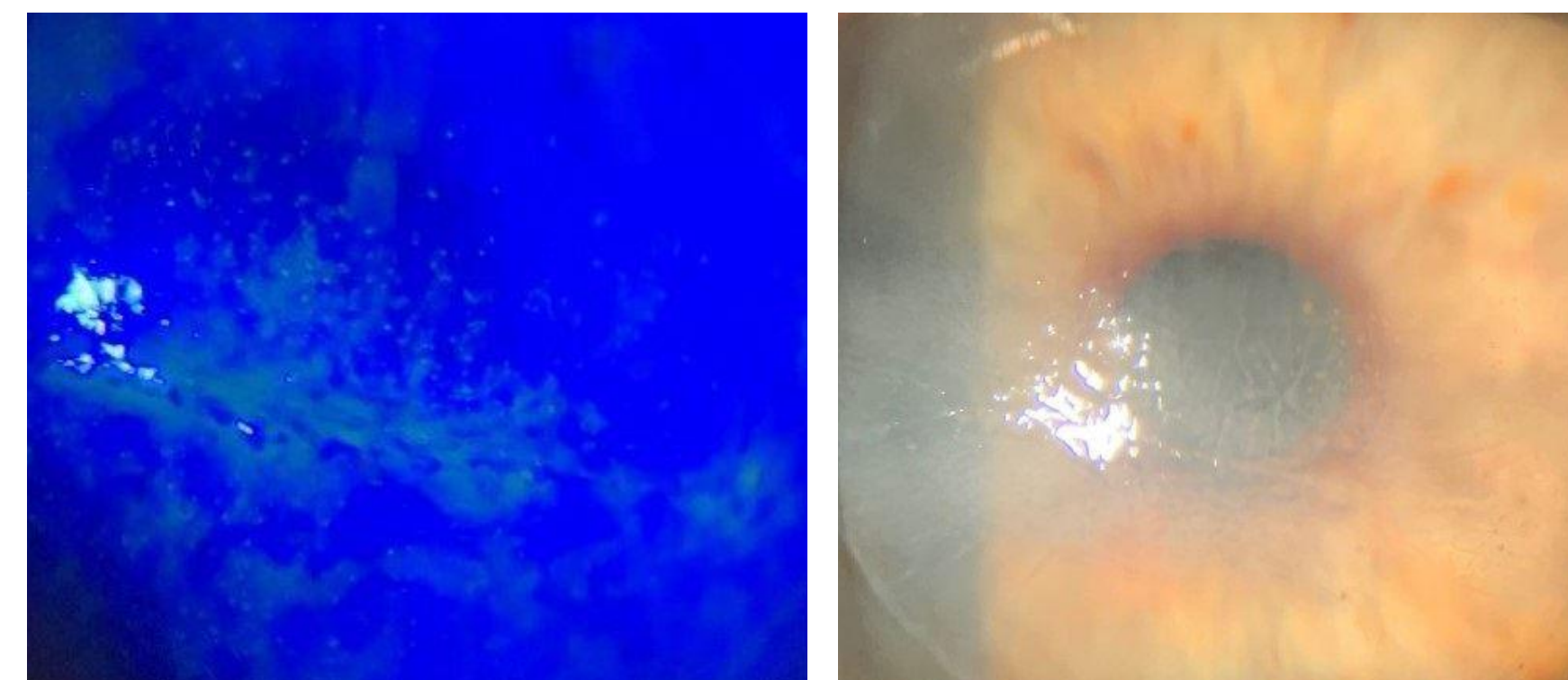


Figure E: One month post management with scleral lens wear OS

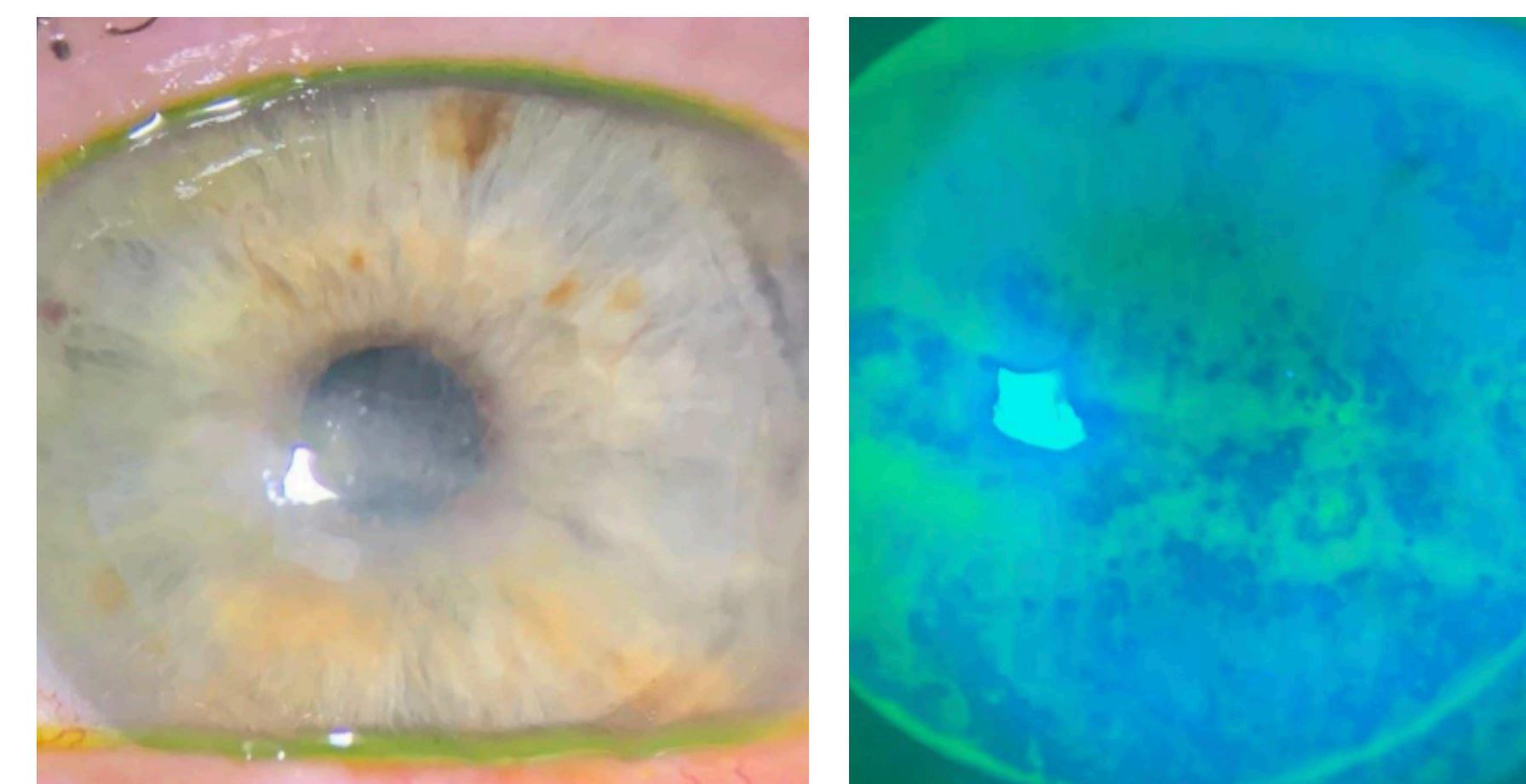


Figure F: Three months post management with scleral lens wear OS

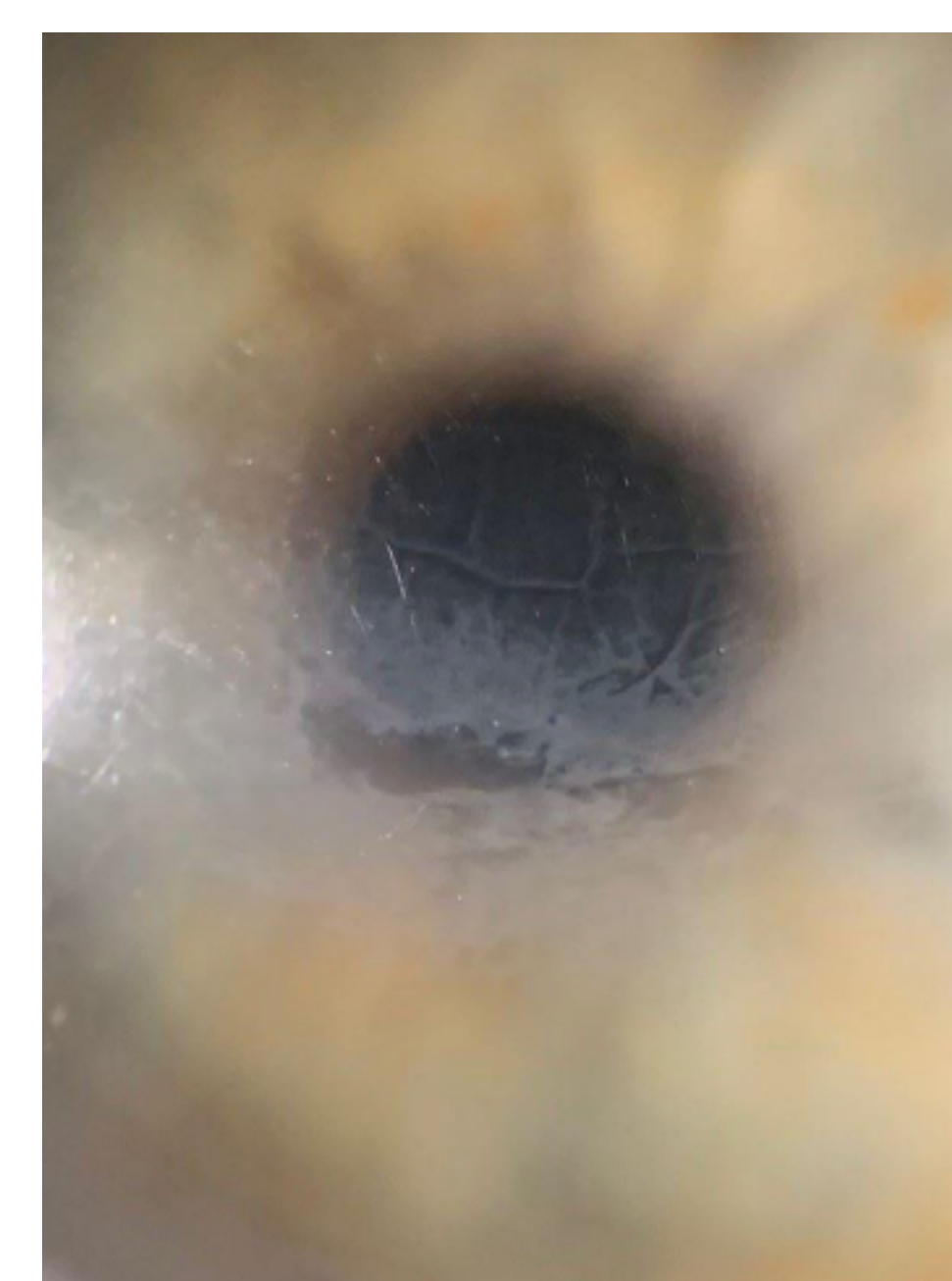
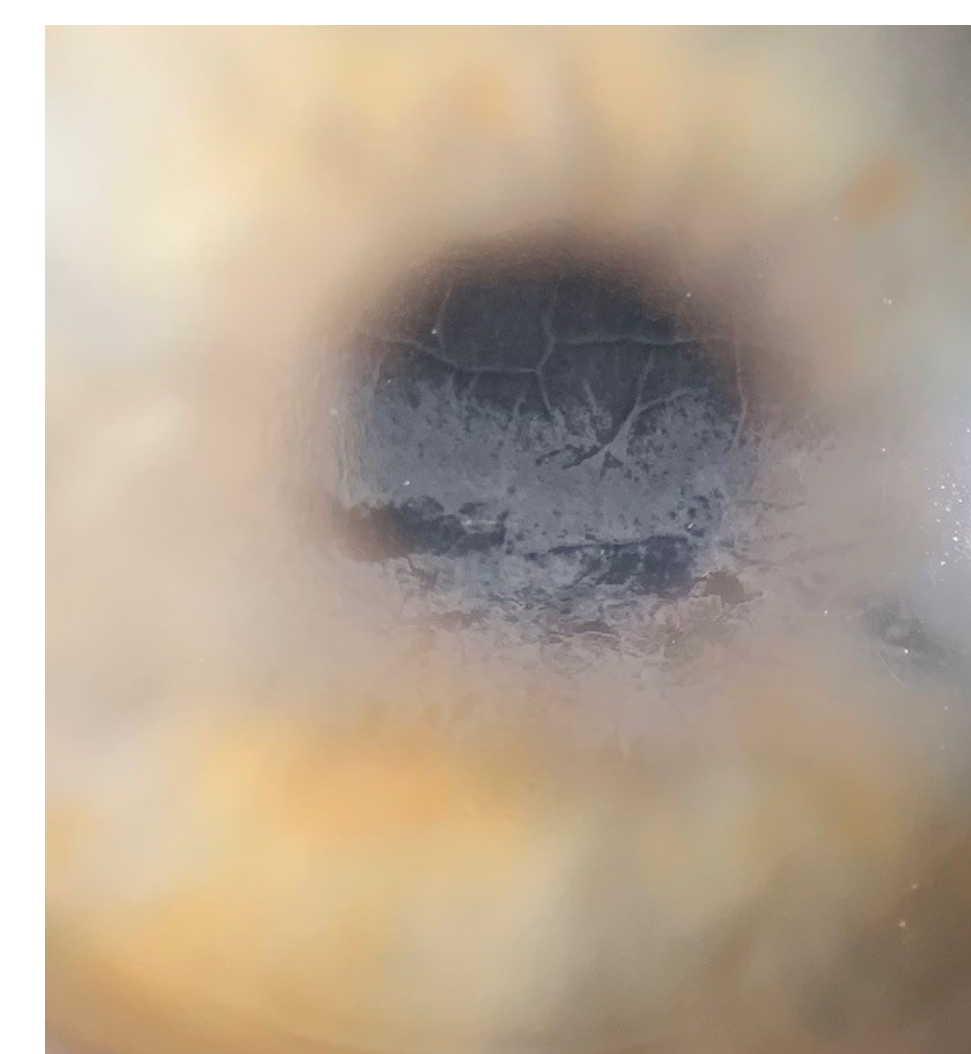


Figure G: Six months post management with scleral lens wear OS

YAG CAPSULOTOMY

Given stable ocular surface and clearing corneal opacification, patient undergoes a yag capsulotomy which improves vision from Count Fingers to 20/150. Visual limiting factors continue to be corneal scarring and epiretinal membrane.

ONE YEAR FOLLOW-UP



Patient is now monitored every six months with improving corneal clarity and no recurrent epithelial defects wearing the scleral contact lens.

Figure H: One year post management with full day time scleral lens wear OS

Discussion

Decreased or loss of corneal sensory innervation leads to reduced reflex tearing, blinking rates, lubrication and epithelial healing which thereby increases risk of corneal injury. Early diagnosis is key in managing NK through a detailed patient history identifying risk factors, slit lamp evaluation and staining, Schirmer's testing, corneal sensitivity measurements (cotton thread method vs. Cochet-Bonnet) and corneal nerve imaging. Treatment is based on severity of the condition; avoid epithelial breakdown, promote healing, reduce stromal scarring and prevent corneal ulceration/perforation.

- **Topical:** lubricants, steroids, antibiotics, anti-inflammatory, cenergem (nerve growth factor), intranasal stimulation
- **Systemic:** vitamin C, omega-3, macrolides, tetracyclines, antivirals
- **Surgical:** punctal cauterization, tarsorrhaphy, direct neurotization
- **Protective:** bandage and scleral contact lenses, Botox, lid weight, punctal occlusion, amniotic membrane

Conclusion

While there can be multiple causes of trigeminal denervation, early diagnosis and screening tools prevent disease progression and severity. Once identified, treatment for NK targets restoring, regenerating and preserving the ocular surface. This case illustrates the important combination of short-term topical treatment with the long-term therapeutic role of scleral contact lenses to heal and protect the health of a vulnerable cornea.

References

1. Beckman K, Milner M, Sheppard J, Yeu E. Advances in the Treatment of Neurotrophic Keratitis; Approaches for Corneal Healing. 2020/6/1
2. Duncan N, Houser K, & Khandelwal S. (2022, July 26). *Neurotrophic Keratitis: A Review*.
3. Pflugfelder SC, Massaro-Giordano M, Perez VL, et al. Topical recombinant human nerve growth factor (cenergermin) for neurotrophic keratopathy: a multicenter randomized vehicle-controlled pivotal trial. *Ophthalmology*. 2020;127(1):14-26.

