

Background

Keratoconus is a non-inflammatory cornea ectasia that leads to thinning and irregular astigmatism. This results in distortion of vision not corrected by conventional glasses or contact lenses. Often a medically necessary contact is required. Patients with keratoconus tend to have decreased visual performance due to higher-order aberrations.¹ Several studies have reported a more significant reduction in aberrations when front surface eccentricity is incorporated into the lens optics.^{2,3}

Case History

A 31-year-old Hispanic male presented for a medical contact lens evaluation. He has a history of keratoconus OU.

The patient failed out of hybrid lens due to lens discomfort and suboptimal vision with significant ghosting of the letters in both eyes. This suggested that patient was still having residual higher-order aberrations (HOA). The patient was refit into a lens with front surface eccentricity options to mitigate aspects of HOA.^{2,3}

Clinical Findings

Visual acuities with habitual spectacles:
 OD: 20/50+, (ghosting), 20/40-2 with pinhole
 OS: 20/40-2, (ghosting), NI with pinhole

Biomicroscopy

OD: moderate thinning; enlarged corneal nerves, staining at cone apex
 OS: moderate thinning; enlarged corneal nerves, trace spk inferiorly at limbus

Topography

OD: nipple cone keratoconus with inferior steepening and irregular astigmatism
 OS: keratoconus with inferior steepening and irregular astigmatism

Pachymetry

OD: 501µm
 OS: 594µm

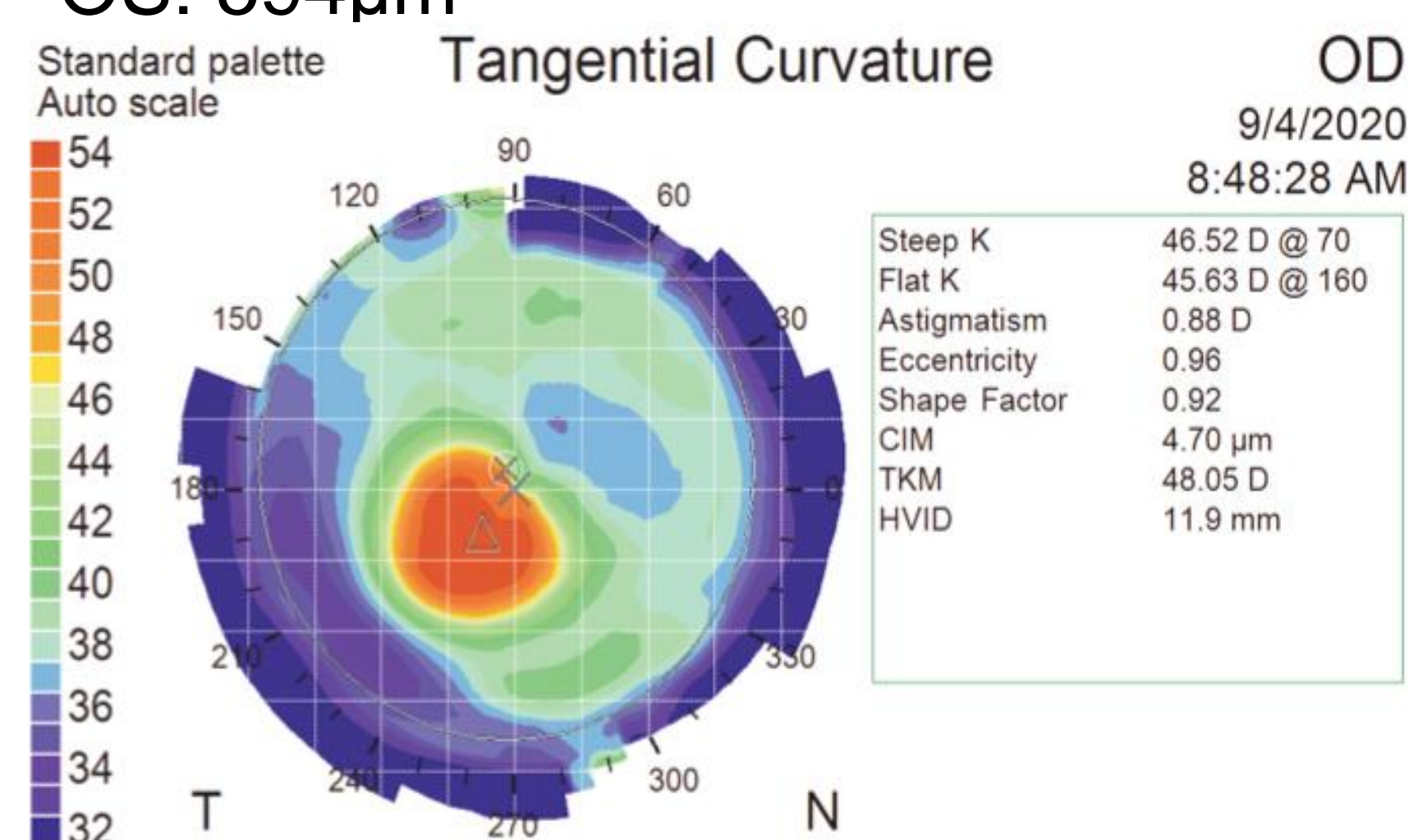


Figure 1 Topography of Right eye, note the high eccentricity value of 0.96

Treatment and Management

Initial lenses ordered

OD: BostonSight SCLERAL 8.0/18.0/2600 sag/ STD Haptic/ FSE1/+2.25-0.50x 045
 VA 20/60 with significant ghosting, PH 20/20
 Dot 080
 Orx:+1.50 +1.50x 121, VA 20/25-1, patient reported ghosting images

OS: BostonSight SCLERAL 8.0/18.0/2550 sag/ STD Haptic/ FSE1/+0.75 DS
 VA 20/30
 Dot 185
 Orx: +1.00 DS, VA 20/20-2

Refit with FSE2 Trial Lens

OD: BostonSight SCLERAL 8.0/18.0/3200 sag/STD haptic/FSE2/Plano
 VA 20/20-1
 Dot 085
 Orx: +1.00 DS, VA 20/20-1 significant improvement in clarity per pt

Second lenses ordered

OD: BostonSight SCLERAL 8.0/18.0/2650 sag/ STD Haptic/ FSE2/+1.75-0.50x 045
 VA 20/20-3 (soft)
 Dot 090. Orx: +1.00 DS, VA 20/20-1

OS: BostonSight 8.0/18.0/2600 sag/STD Haptic/ FSE1/+1.75 DS
 VA 20/25-1.
 Dot 145. Plano, VA 20/20-1

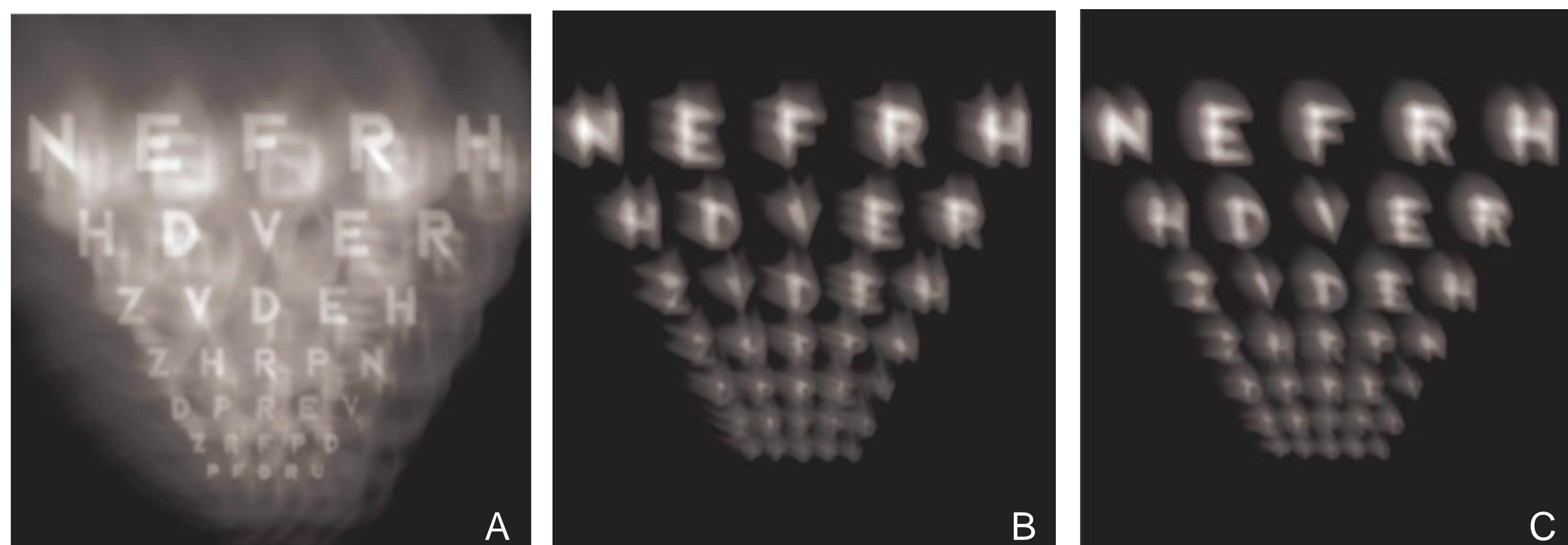


Figure 2 Image simulation based on HOAs. A) Vision without correction. B) Vision with FSE1 BostonSight SCLERAL lens C) Vision with FSE2 BostonSight SCLERAL lens

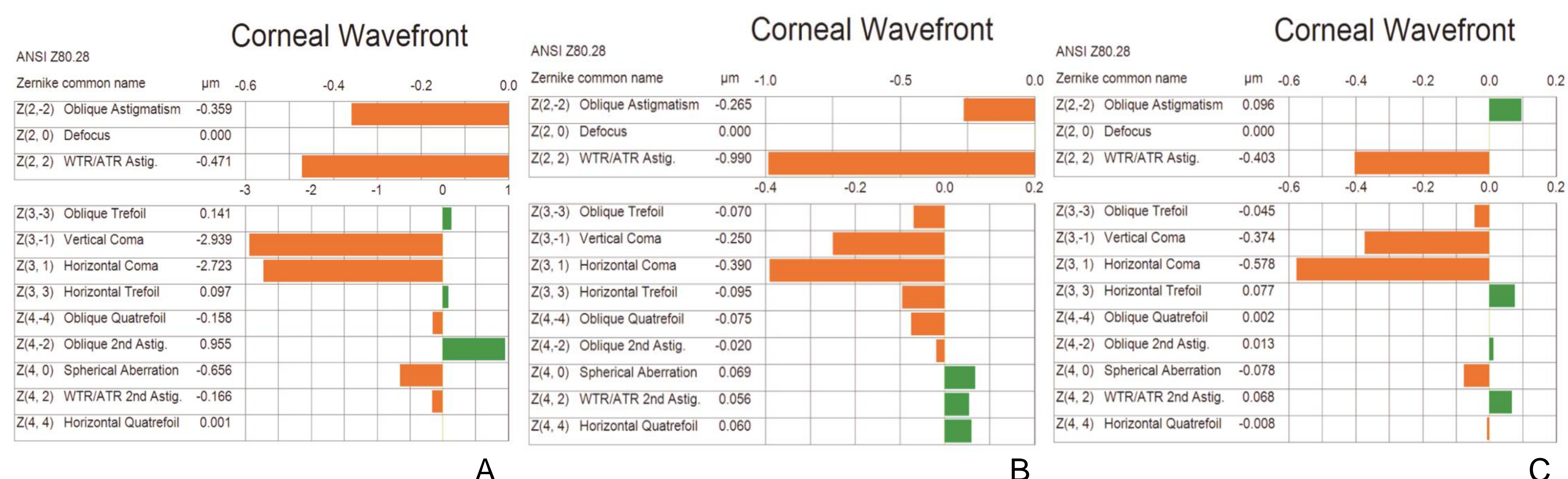


Figure 3 HOAs in Zernike polynomial terms. A) HOAs without correction. B) HOAs with FSE1 BostonSight SCLERAL lens C) HOAs vision with FSE2 BostonSight SCLERAL lens

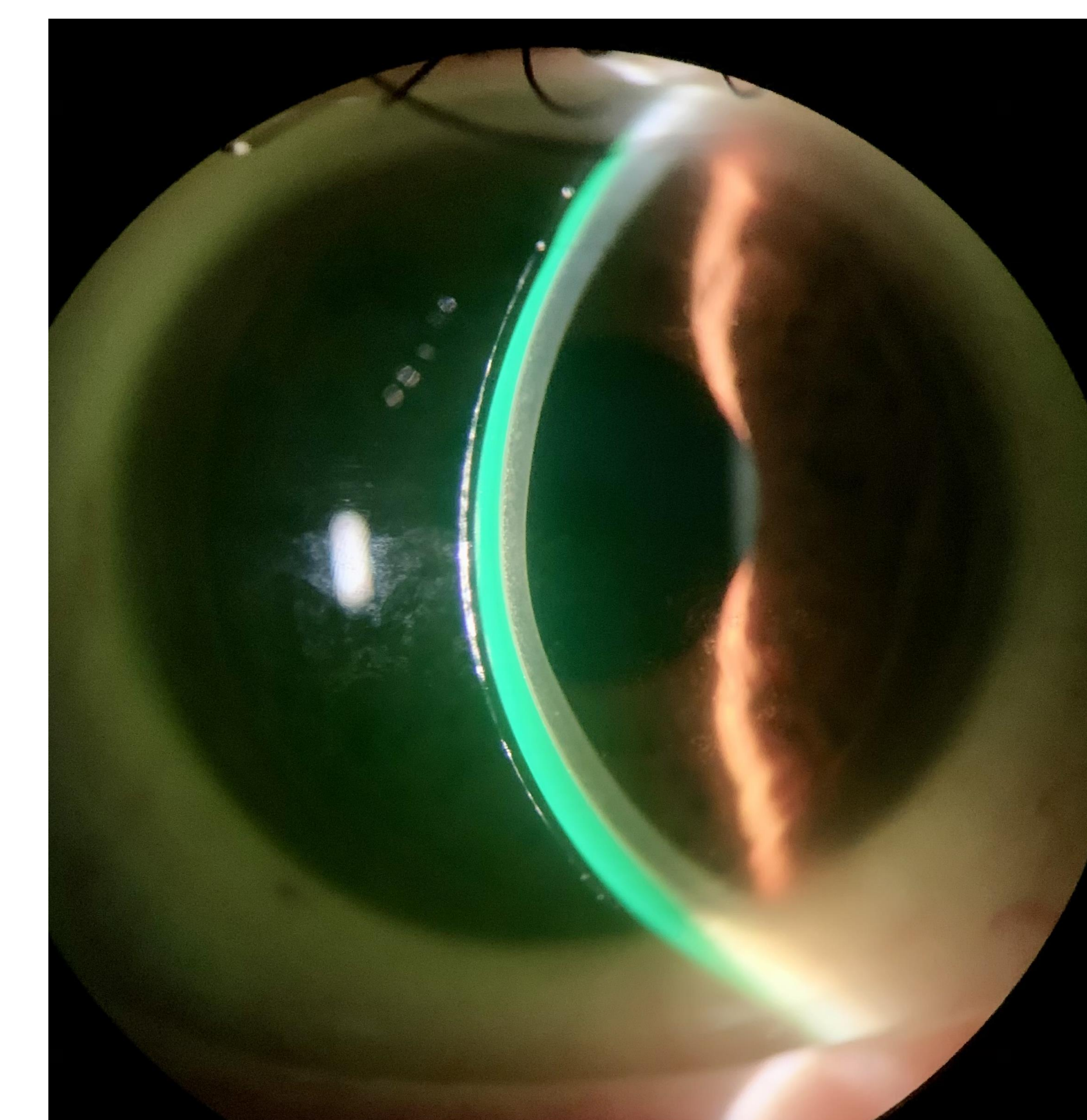


Figure 4. Adequate central clearance on right eye

Conclusion

Keratoconus is a progressive condition. As the cornea continues to change, it becomes increasingly difficult to achieve a satisfactory contact lens fit.⁴ Current standard of care is rigid gas permeable lenses can partially mask the cornea irregularities; however, aberrations can remain.¹

Higher-order aberration creates a unique challenge when fitting keratoconus patients in specialty lens. Utilizing a lens that incorporates front surface eccentricity can help cases where vision remains limited despite using an adequately fit scleral lens. Gummus reported that lens with front surface optical eccentricity had a greater reduction in spherical aberrations than lens without eccentricity adjustment.² The best visual acuity corresponded with the amount of eccentricity that provided the best low contrast.³

HOA correction rates of up to 96% have been found with BostonSight scleral lens.² As well as an improvement in visual acuity of at least three lines.² This can profoundly impact a patient's quality of life and their daily living activities

References

- Hastings GD, Applegate RA, Nguyen LC, Kauffman MJ, Hemmati RT, Marsack JD. Comparison of Wavefront-guided and Best Conventional Scleral Lenses after Habituation in Eyes with Corneal Ectasia. *Optom Vis Sci.* 2019 Apr;96(4):238-247.
- Gummus K, Gire A, Pflugfelder SC. The impact of the Boston ocular surface prosthesis on wavefront higher-order aberrations. *Am J Ophthalmol.* 2011 Apr;151(4):682-690.e2.
- Hussein T, Le HG, Carrasquillo KG, Johns L, Rosenthal P, Jacobs DS. The effect of optic asphericity on visual rehabilitation of corneal ectasia with a prosthetic device. *Eye Contact Lens.* 2012 Sep;38(5):300-5.
- Baran I, Bradley JA, Alipour F, Rosenthal P, Le HG, Jacobs DS. PROSE treatment of corneal ectasia. *Cont Lens Anterior Eye.* 2012 Oct;35(5):222-7.
- Barnett M, Johns LK. *Contemporary Scleral Lenses: Theory and Application.* Vol 4. Sharjah, UAE: Bentham Science Publishers; 2017.